

Presentación inusual de glomerulopatía inducida por consumo de tiamazol: reporte de caso

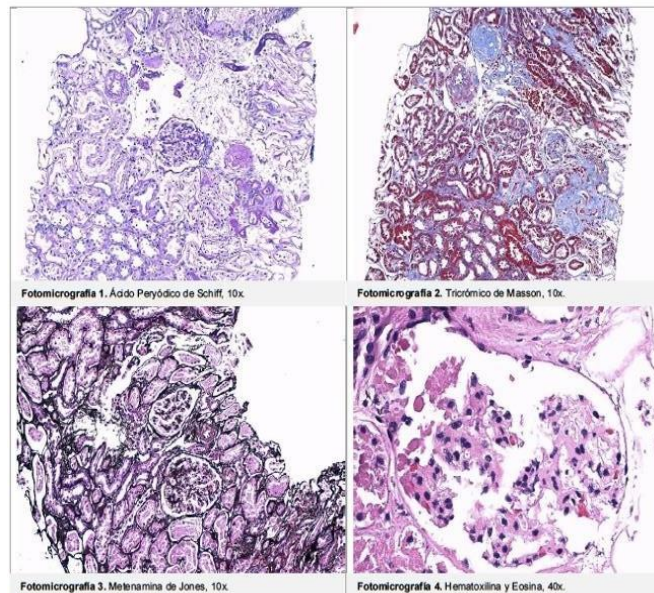


Figura 1

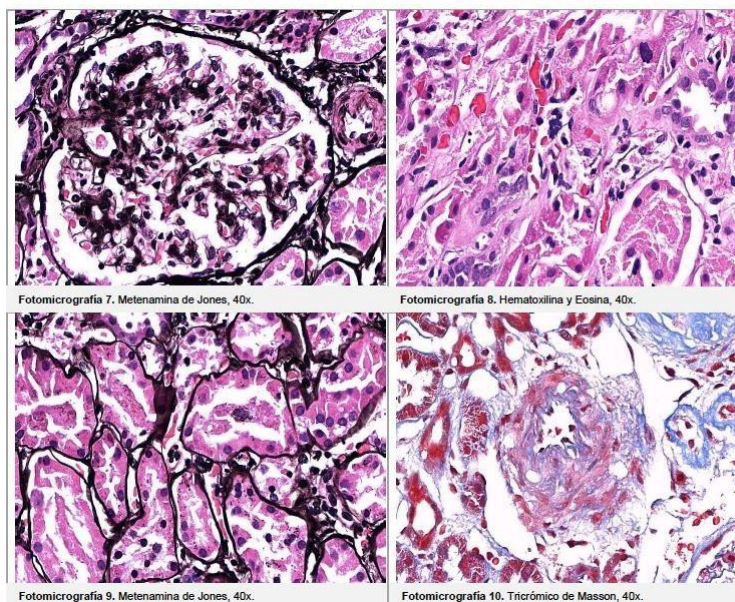


Figura 2

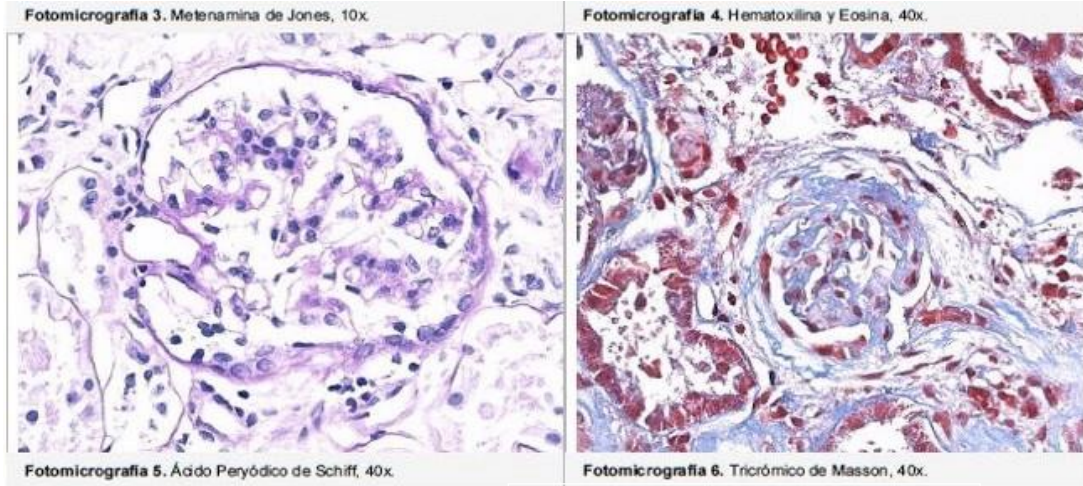


Figura 3

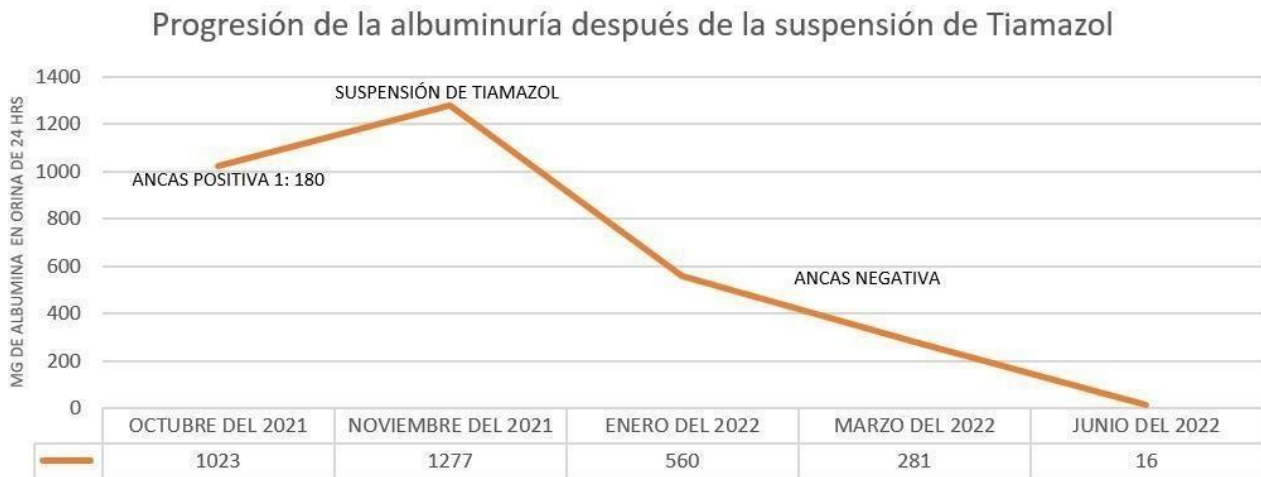

Figura 4