

Transvaginal fecal leak, an unusual presentation of a gastrocolic fistula, a case report

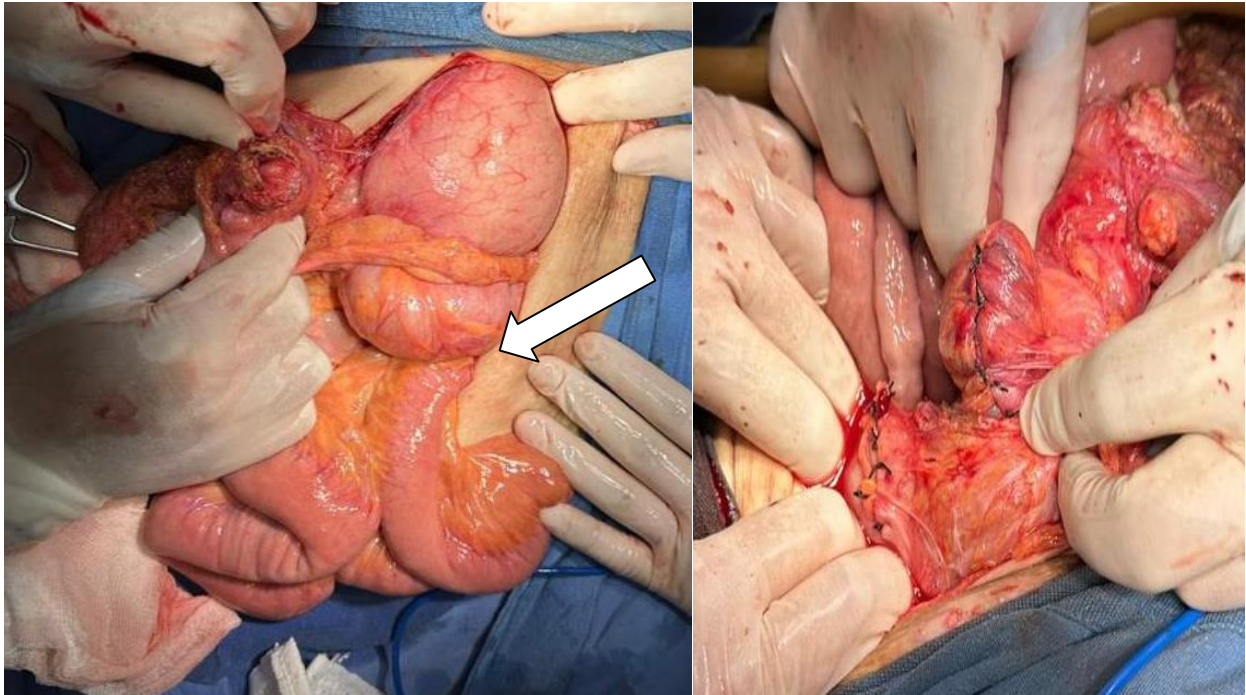


Fig 1. The 2 ends of the repaired fistula can be seen Fig 2: white arrow location of gastrocolic fistula

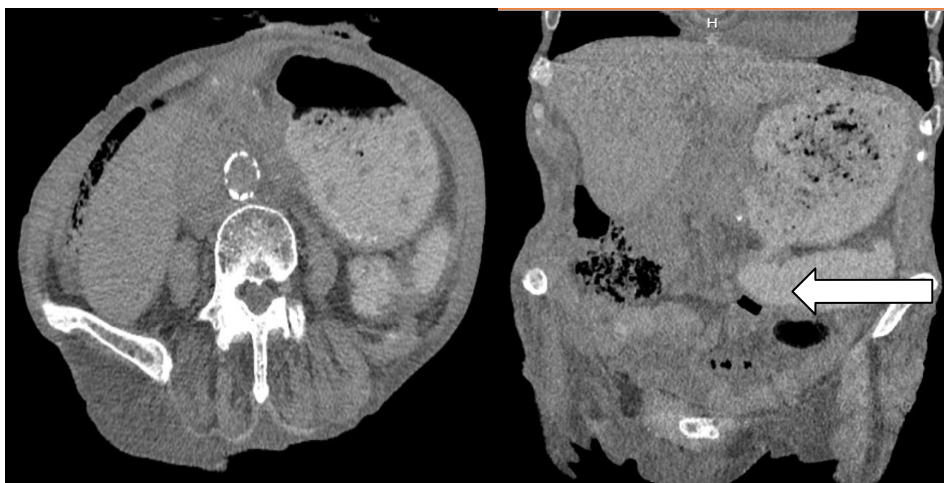

Fig 4. White arrow: finding by tomography of fistula location with passage of the contrast medium towards the colon