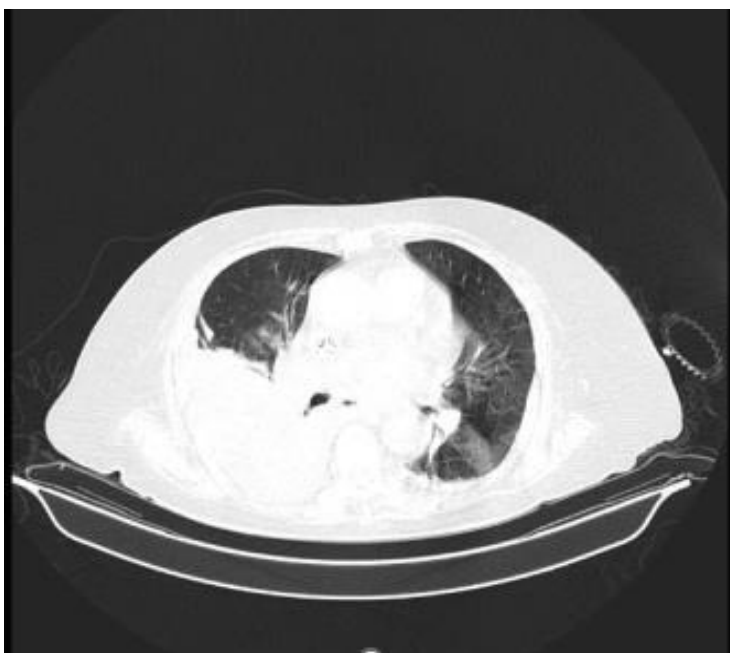
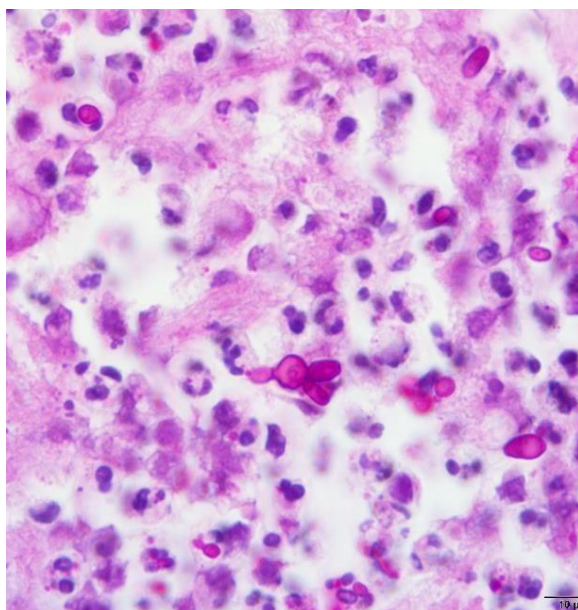


Paracoccidiomicosis pleuropulmonar: a propósito de un caso



TAC simple de tórax



Estudio histopatológico de líquido pleural