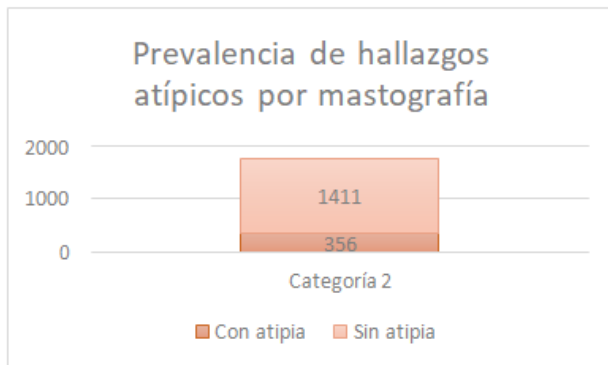
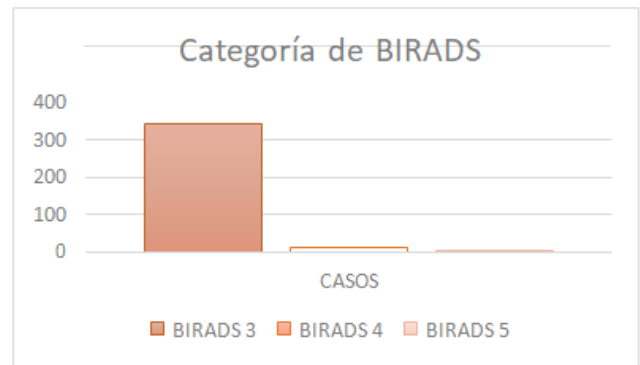


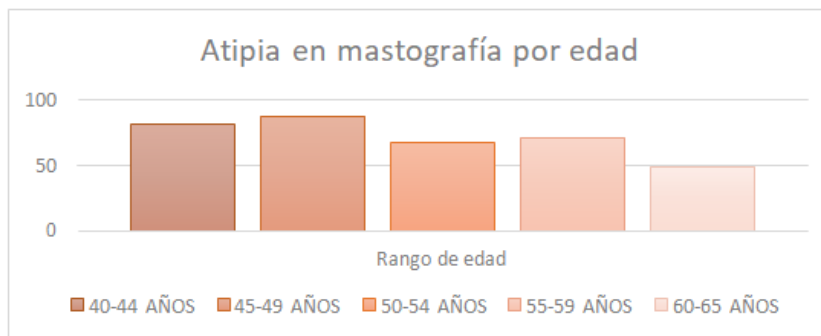
Hallazgos atípicos en las mastografías de pacientes de 40 a 65 años de una Unidad de Medicina Familiar en Guadalajara, México



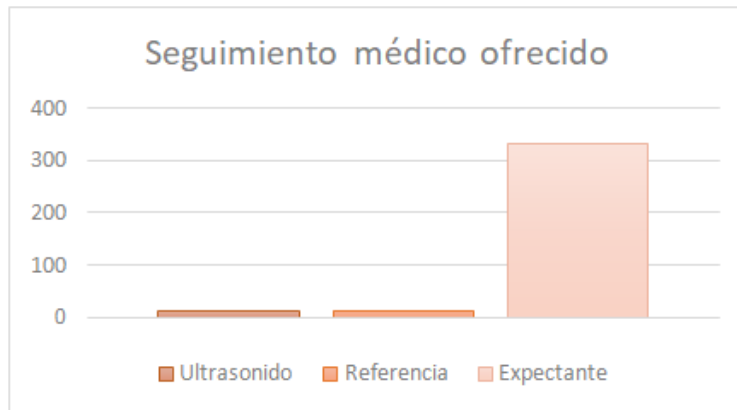
Gráfica 1



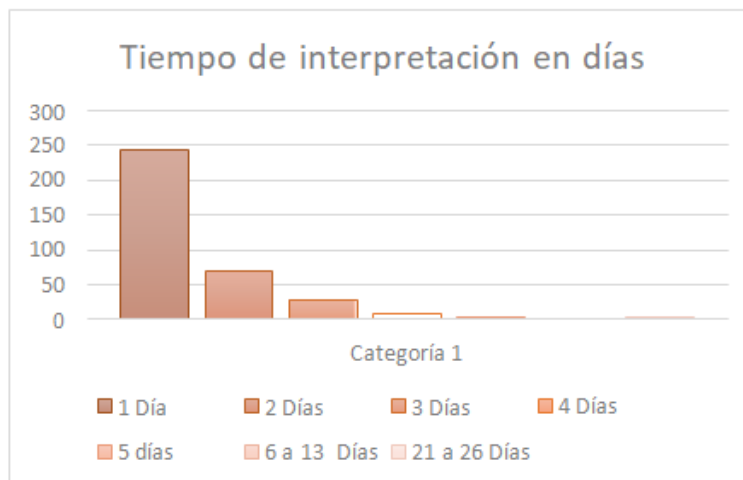
Gráfica 2



Gráfica 3



Gráfica 4



Gráfica 5